

# Laser-assisted treatment of peri-implantitis: a retrospective cohort study

Gary M. Schwarz, DDS, MSD ■ David M. Harris, MS, PhD

The intent of this study was to provide a retrospective analysis of the clinical outcomes of 222 consecutive patients with 437 implants diagnosed with peri-implantitis and treated with the LAPIP protocol. All patients treated with LAPIP therapy at this practice were included. The primary outcome variable studied was probing depth (PD), and secondary variables were erythema, bleeding on probing, and suppuration. The significance of reductions in PD and clinical signs was assessed using repeated-measures analysis of variance. Complete data for both baseline and follow-up visits were available for 116 patients with a total of 224 treated implants. The rate of successful treatments—defined as follow-up PD  $\leq$  4.0 mm and elimination of clinical signs—was 90%. The reduction in PD from 5.4 mm at baseline to 3.4 mm at a median of 7.6 months was statistically significant ( $P \leq 0.001$ ). The reduction in the frequency of clinical signs was also statistically significant ( $P \leq 0.001$ ). Among 138 patients who had follow-up visits but not necessarily complete PD data, 15 implants were recorded as failed and 249 were recorded as intact at the median longest follow-up time of 13.1 months, resulting in a survival rate of 94%. In this single clinical practice, use of the minimally invasive LAPIP protocol for the treatment of peri-implantitis provided effective and predictable clinical outcomes. Future randomized controlled trials are indicated.

**Received:** April 16, 2019

**Accepted:** September 17, 2019

**Key words:** dental implant, dental laser, laser-assisted peri-implantitis procedure, peri-implantitis

Published with permission of the Academy of General Dentistry.  
© Copyright 2020 by the Academy of General Dentistry.  
All rights reserved. For printed and electronic reprints of this article for distribution, please contact [jkaetha@mossbergco.com](mailto:jkaetha@mossbergco.com).

**GENERAL DENTISTRY  
SELF-INSTRUCTION**



Exercise No. GD456, p. 26

Subject code: Laser Therapy/Electrosurgery (135)

Recent review articles analyzing thousands of publications present a consensus that a consistently effective treatment for peri-implantitis is yet to be developed.<sup>1-8</sup> Numerous trials and studies have examined the clinical outcomes following a variety of treatments and treatment combinations and reported a wide range of outcomes, from no significant effect to promising positive results.

Resective therapies eliminate the causative factors of peri-implantitis mainly by cleaning the implant surface and debridement of infected tissues. Minimally invasive protocols for mechanical debridement use ultrasound or curettes or are combined with various modes of antibiotic delivery.<sup>9-13</sup> Some approaches include laser surface decontamination.<sup>14-16</sup> These treatments demonstrate some efficacy for peri-implant mucositis but are generally ineffective against more advanced cases of peri-implantitis.

Regenerative therapies aim to reproduce osseointegration and restore the original morphology.<sup>17,18</sup> These protocols often involve open access flap surgery combined with bone grafts and membranes for guided tissue regeneration.<sup>19,20</sup> These more invasive and complex approaches show some positive but inconsistent and unpredictable outcomes.

Among the protocols showing promise in the treatment of peri-implantitis are those involving dental lasers. Virtually all dental laser types—diodes; neodymium-doped yttrium-aluminum-garnet (Nd:YAG); erbium, chromium-doped yttrium-scandium-gallium-garnet (Er,Cr:YSGG); erbium-doped yttrium-aluminum-garnet (Er:YAG); and carbon dioxide (CO<sub>2</sub>)—have been demonstrated to be effective for decontamination of implant surfaces, but most provide only marginal improvement in clinical efficacy when combined with other therapies.<sup>14,21-27</sup>

The proprietary name *LAPIP* (Millennium Dental Technologies) is derived from the acronym for *laser-assisted peri-implantitis procedure*. The LAPIP protocol is a minimally invasive Nd:YAG laser-based surgical procedure that involves both soft tissue and osseous tissue components. Honigman and Suzuki described LAPIP therapy and presented 3 case reports of positive outcomes.<sup>28,29</sup> Nicholson et al examined radiographs of 16 patients treated with the LAPIP protocol.<sup>30</sup> They measured the areas of interproximal vertical defects before and after LAPIP treatment and reported consistent and progressive crestal bone fill over 2-3 years after the initial treatment.

This article reports a longitudinal retrospective cohort study of the clinical outcomes of the LAPIP protocol for the treatment of peri-implantitis as applied in the single-investigator private practice of one of the authors (GMS). The private practice in McAllen, Texas, began treating peri-implantitis with LAPIP therapy in October 2013. A retrospective analysis of the entire

cohort—222 LAPIP patients with 437 implants treated from October 2013 through September 2016—was conducted.

## Materials and methods

According to the manufacturer, LAPIP therapy is indicated when inflammation, excessive probing depth (PD), bleeding on probing, and/or suppuration are present. Bone loss is estimated by sounding the bone under anesthesia (step 1, described later) and examining radiographic evidence. At least 1 of 6 sites around the implant circumference must have a PD of  $\geq 4$  mm along with bleeding and/or suppuration. Namely, all implants must have a clinical diagnosis of peri-implantitis. Implants with peri-implant mucositis, an inflammatory reaction involving only the mucosal tissue around a dental implant, are not indicated for the LAPIP procedure (Fig 1).

### Data collection

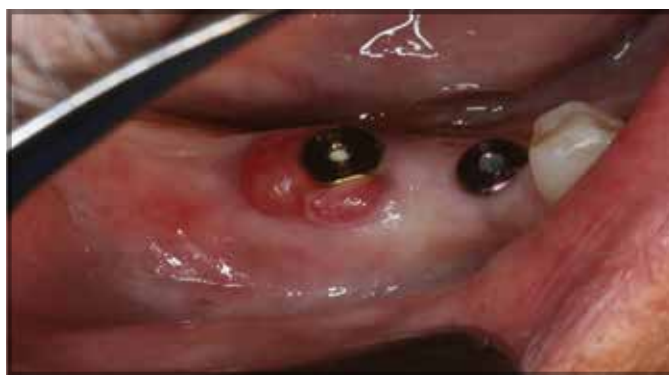The data collection and analysis protocol were approved by a private institutional review board (Quorum Review), and the principles of the Declaration of Helsinki and good laboratory practice guidelines were followed throughout the study. Patient records were examined to identify patients who had received LAPIP treatment. All LAPIP patients were accounted for, and no patients were excluded from the study. Data were captured from patient records and identifying information was redacted, and the data were then entered into case report forms. The completed case report forms were scanned and forwarded electronically to the statistician for data entry and analysis, and the hard copy was retained onsite.

### Laser dosimetry

The dental laser used in this study was a 6-W, free-running, pulsed Nd:YAG laser (PerioLase MVP-7, Millennium Dental Technologies) with an output in the near-infrared spectrum at a wavelength of 1064 nm. High-energy pulses of light are delivered to the tissue through an optical fiber terminating in a handpiece. The fiber extends a few millimeters from the distal end of the handpiece and is inserted into the pocket (step 2).

The energy delivered during pass 1 and pass 2 was recorded separately for 138 treatments. Regression analysis determined the average dosimetry used in this study, but there was considerable variability from case to case. Pass 1 required, on average, an initial 130 J for all implants, and pass 2 required an initial 85 J. Added to these initial values was energy based on the PD:  $10\times$  the mean baseline PD in joules for pass 1 (10 J per mm of PD), and  $4\times$  the mean baseline PD for pass 2 (4 J per mm of PD).<sup>31</sup>

LAPIP treatment includes a series of surgical endpoints. For example, during pass 1 of the laser, the operator must remove the diseased pocket epithelium. Significant variation is encountered from case to case in the time needed to accomplish this based on differences in the surgical environment and tissue conditions. Hence, a prescribed light dose does not determine the surgical endpoint; rather, achievement of the surgical endpoint determines the total joules. Dosimetry provides guidance, and a well-trained surgeon understands that clinical conditions influence the selection of parameters and the final energy delivered.



**Fig 1.** In peri-implant mucositis, inflammation is confined to the mucosa surrounding the dental implant without signs of bone loss.

### LAPIP steps

The manufacturer's instructions divide LAPIP treatment into steps: (1) The defect depths are determined by probing under local anesthesia; (2) the Nd:YAG laser is used in ablation mode to selectively remove the diseased pocket epithelium and open the pocket to gain access to the implant surface (pass 1); in this first pass, the Nd:YAG laser energy destroys pathogens on the implant surface and penetrates several millimeters into the surrounding tissues; (3) accretions and/or excess cement are removed from the implant surface with specialized hand instruments and a piezoelectric ultrasonic scaler; (4) the alveolar bone is decorticated to stimulate bleeding and cause release of stem cells and growth factors; (5) the laser is used in hemostasis mode to help form a stable adhesive fibrin clot (pass 2); (6) finger pressure is applied to assist adherence of the gingiva to the implant surface and achieve wound closure; (7) occlusal interferences are removed from the implant crown, if it is still intact. After treatment is completed, healing and tissue regeneration proceed over several months.<sup>18,30,32</sup> Patients are maintained on a schedule of regular hygiene visits.

### Inclusion and exclusion criteria

The entire cohort of private practice patients diagnosed with peri-implantitis were candidates for the LAPIP procedure. The differential diagnosis between peri-implant mucositis and peri-implantitis is a matter of academic debate.<sup>33</sup> The private practice in this study uses the American Academy of Periodontology's definition of *peri-implantitis*: "an inflammatory process around an implant which includes both soft tissue inflammation and loss of supporting bone."<sup>34</sup>

There were 4 subgroups within the entire cohort. Analysis of each subgroup excluded patients with missing data. The entire cohort of 222 patients were treated with the LAPIP protocol. Nineteen patients were lost to follow-up, and 65 patients had follow-up appointments outside the study period. The second group of 196 patients provided baseline and demographic data. The third group of 138 patients had follow-up visits to assess whether the treated implant was intact or missing. This subgroup was used to calculate median first and longest follow-up times, determine when the failed implants were lost, and estimate the survival rate. The fourth group of 116 patients with 224 implants had complete outcome measurements at both

**Table 1.** Medical conditions of 196 patients with recorded baseline data.

Medical history	Patients	
	No.	%
No relevant history	71	36
Smoking	22	11
Diabetes mellitus	31	16
Cardiovascular disease	102	52
Anticoagulant use	37	19
Immunocompromise	11	6
Bisphosphonate use	7	4
Chemotherapy	8	4

**Table 2.** Probing depth (PD) in patients with complete baseline and follow-up data (n = 116).

Value	Baseline PD, mm	Follow-up PD, mm	Change in PD	
			mm	%
Mean (SD)	5.4 (1.8)	3.4 (2.5)	2.0 (2.5)	37
Median (range)	4.9 (3 to 11)	2.8 (0 to 12)	2.1 (-8 to 8)	43 (-213 to 100)
95% CI	5.1 to 5.7	3.0 to 3.9	1.5 to 2.4	25 to 42
P value			< 0.001	< 0.001

Mean PD as measured at 6 sites per implant. Both the absolute change (repeated-measures analysis of variance) and the percentage reduction in PD (*t* test) at a median follow-up of 7.6 months are statistically significant ( $P < 0.001$ ).

baseline and at least 1 follow-up. One implant per patient was selected for statistical analysis (n = 116). All 224 implants from this group were followed through multiple treatments.

### Clinical signs

All PDs captured in this study were measured and recorded by a single dental hygienist. Prior to the surgical procedure and after administration of local anesthesia and, occasionally, light conscious sedation, the dentist probed the sites to understand the defect geometry. Secondary outcome measures were clinical signs of bleeding, suppuration, and erythema, which were evaluated and entered into the patient's record as yes or no.

### Statistical analyses

A sample of the total population having complete baseline and follow-up data was tested to determine whether there was a statistically significant reduction in PD and an improvement in clinical signs following LAPIP treatment.

Demographic, medical history, treatment, and outcome variables were summarized descriptively with 95% confidence intervals, which were used to quantify the improvement in PD and the percentage improvement in secondary outcome measures. The primary outcome variable was the improvement in PD from baseline to the patient's first follow-up visit. The mean PD calculated from 6 measurements per implant was used. The statistical design chosen used the subject as the primary unit of analysis so that only 1 implant per patient was analyzed; the implant with the greatest baseline PD was chosen for analysis. Secondary outcome variables included the percentage of failed implants and the occurrences of bleeding on probing, suppuration, and erythema, scored as yes or no. The primary treatment variable was the light dose, measured in joules.

The statistical significance of PD changes was analyzed using repeated-measures analysis of variance. Since greater baseline PDs have potential for greater changes in PD at follow-up, the percentage of change was also presented descriptively and tested with a *t* test. A McNemar chi-square test was used to assess the

significance of changes in the frequencies of occurrence of clinical signs of bleeding, suppuration, and erythema.

## Results

### Clinical outcomes

A total of 222 patients with 437 dental implants were treated with the LAPIP protocol over a period of 3 years from October 2013 through September 2016. Of these patients, 30% (n = 67) had implants placed at other clinics. No adverse events related to treatment were identified from the patient records provided on the case report forms.

The baseline demographic information and medical profiles of a sample of 196 of 222 patients who had complete baseline data were assumed to be representative of the entire study population. This group comprised 93 male and 103 female patients with a mean (SD) age of 65.8 (12.5) years (range of 23-98 years). Seven medical conditions provided a generalized list of putative risk factors (Table 1).

All implants recorded as failed during the study period were identified. A total of 135 patients had a single implant treated; 45 patients had 2 implants treated; and 42 patients had 3 or more implants treated, for a total of 437 implants. One patient had a full-mouth restoration with 20 implants, all of which were treated. Implants varied by location, type, and size and were characterized as prerestorative (n = 70 [16%]) or postrestorative (n = 367 [84%]). The crowns were removed prior to treatment to provide access in only 7 (2%) of the 363 implants that presented with crowns attached. Possible etiologies of peri-implantitis were listed as malocclusion (n = 159 [36%]), cement related (n = 119 [27%]), position related (n = 10 [2%]), or poor oral hygiene (n = 13 [3%]). There were no obvious relationships among these factors and the clinical outcomes.

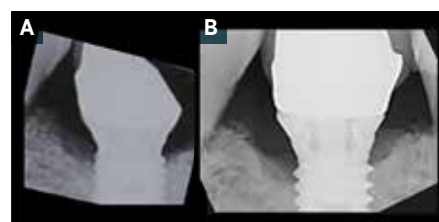
There were 138 patients (264 implants) who had follow-up visits but not necessarily complete records of PD and other clinical data. The survival rate was determined from this group. The median time to first follow-up was 7.6 months, and the median time to longest follow-up was 13.1 months. The survival rate at 13.1 months was 94% (249 of 264 implants intact).

**Table 3.** Frequency of clinical signs at selected implants in patients with complete data at baseline and first follow-up (n = 116).<sup>a</sup>

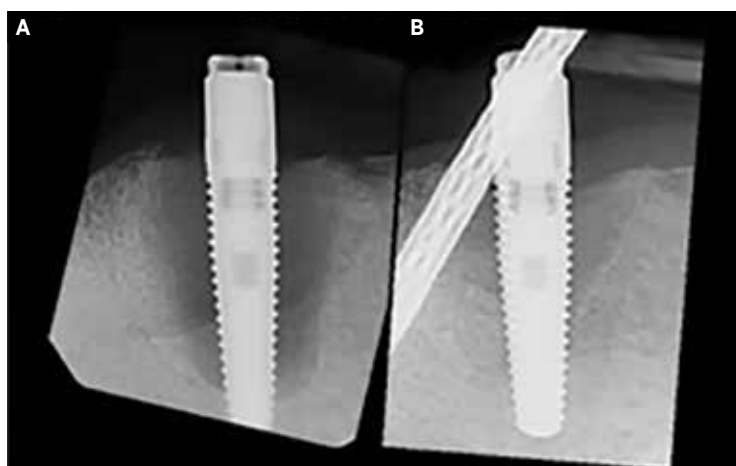
Sign	No. (%) with signs			Improved (No.)	Reduction (%)	95% CI
	Baseline	Follow-up	P value			
Bleeding	105 (91)	23 (20)	< 0.001	82	78	67-86
Suppuration	46 (40)	9 (7)	< 0.001	37	83	66-93
Erythema	73 (63)	14 (12) <sup>b</sup>	< 0.001	62	85	72-93

<sup>a</sup>In patients with multiple implants, the implant with the deepest mean baseline probing depth was selected. The difference in the number of implants with each sign at baseline and follow-up is statistically significant ( $P < .001$ ; McNemar chi-square test).

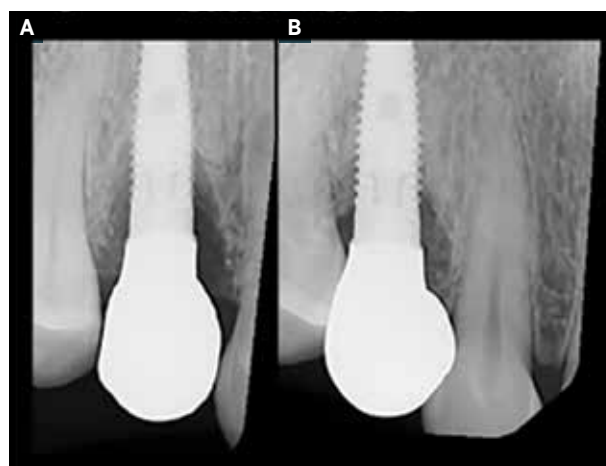
<sup>b</sup>At follow-up, 3 implants showed erythema that was not observed at baseline.



**Fig 2.** Case 1. A. Pretreatment radiograph of implant 30. B. Increase in radiographic density on the mesial aspect 8 months posttreatment, suggesting formation of new crestal bone.



**Fig 3.** Case 2. A. Extensive peri-implant radiolucency at implant 26. B. Significant reduction in the radiolucency by 14 months posttreatment.



**Fig 4.** Case 3. A. Evidence of bone loss at implant 5. B. Complete fill of the distal defect 18 months posttreatment.

For a sample of 116 patients with 224 implants, records provided complete data for PD measurements and clinical signs before and after treatment. Descriptive and comparative statistical tests were performed within this sample to test for the significance of changes in PD and clinical signs following LAPIP treatment. For patients with multiple implants, the implant with the deepest mean baseline PD was selected. Hence, analysis was conducted on fewer implants, and those implants analyzed had deeper PDs. The mean (SD) baseline PD for all 392 implants with available baseline data was 5.0 (2.1) mm. However, in the 1-implant-per-patient group, the mean (SD) baseline PD was 5.4 (1.8) mm, which showed a reduction of 2.0 (2.5) mm at follow-up. This represents a bias added to the analysis to test for the worst case.

The mean reduction in PD at first follow-up after treatment in the 116 patients with complete data is the most conservative estimate of efficacy (Table 2). Among the 116 implants analyzed (1 per patient), 7 failed, 109 were still intact at the longest follow-up, and 103 had a posttreatment reduction in mean PD. The mean baseline PD of 5.4 (1.8) mm was reduced by 2.0 (2.5) mm at a median follow-up time of 7.6 months. A 1-group repeated-measures analysis of the reduction in PD at first follow-up

determined that the reduction was statistically significant ( $P < 0.001$ ). The efficacy, defined as implants exhibiting improvement in PD at first follow-up, was 103 of 116 implants (89%).

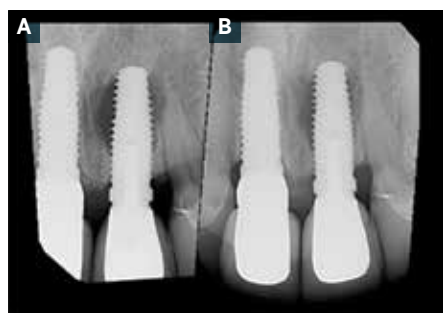
The secondary outcome measures were the clinical signs of bleeding on probing, suppuration, and erythema (Table 3). The most frequent clinical sign was bleeding, which occurred in 91% of the sample. This was reduced by 78% at the first follow-up. Suppuration was reduced by 83%, and erythema was reduced by 85%. The McNemar chi-square test indicated that all changes in clinical signs were statistically significant ( $P < 0.001$ ).

### Case reports

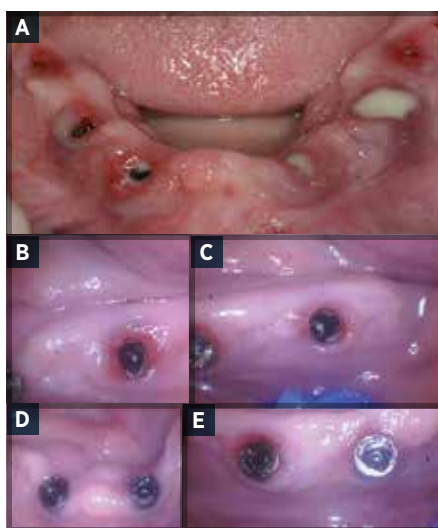
Statistical analysis was performed on 1 selected implant in patients with multiple implants in order to use the patient as the unit of analysis. In this section, the entire group of 224 implants is followed through multiple treatments. Case reports illustrate the variety of outcomes.

#### One treatment

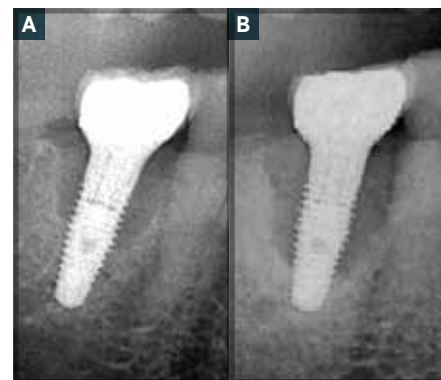
The majority of implants (176 [79% of the sample with complete data]) responded successfully to a single treatment. At about 7 months following treatment, up to 99% of the clinical signs



**Fig 5.** Case 4. A. Periapical lesion around implant 9. B. Significant reduction in the size of the lesion after 2 treatments (20 months following the first treatment).



**Fig 6.** Case 4. Six implants that support a fixed mandibular prosthesis. A. At baseline, all 6 implants exhibit all 3 clinical signs: erythema, bleeding, and suppuration. B-E. Clinical signs are absent 27 months after LAPIP.



**Fig 7.** Case 5. A. Radiographic evidence of bone loss at implant 30. B. Progression of the defect after 3 LAPIP treatments.

of bleeding, suppuration, and erythema had resolved, and the mean PD in this subset had decreased from 4.6 mm at baseline to 2.4 mm.

Case 1 is representative of the sample who received a single effective treatment (Fig 2). A 65-year-old hypertensive man who was taking aspirin twice a day received a single implant in the mandibular right first molar site (implant 30) in 2004. The patient presented in May 2014 with signs of severe inflammation, erythema, bleeding on probing, and spontaneous expression of exudate. The average baseline PD was 4.5 mm; the lingual aspect PDs were 3.0, 3.0, and 3.0 mm, and the buccal wall PDs were 5.0, 8.0, and 5.0 mm. The LAPIP procedure and postoperative period were unremarkable. At the 8-month follow-up visit, the surrounding gingival tissues were tight and pink; erythema, bleeding, and suppuration were absent; and all sites probed 3.0 mm. There was radiographic evidence of what appeared to be new crestal bone, a finding that was not uncommon in this group and consistent with the reports of Yukna et al and Nevins et al.<sup>18,32</sup>

Case 2 involved an 87-year-old man with a cardiovascular condition (Fig 3). Two implants in the lateral incisor positions (implants 23 and 26) supported a mandibular denture. The date of placement was unknown, but recent food impaction at implant 26 caused an infection with severe erythema, bleeding, and suppuration. Pretreatment, a mean PD of 5.7 mm (facial: 7.0, 6.0, and 7.0 mm; lingual: 5.0, 4.0, and 5.0 mm) was accompanied by a large peri-implant radiolucency. At 14 months posttreatment, the clinical signs were gone, the mean PD was reduced to 2.8 mm, and the radiolucency was absent.

The patient in case 3 was a 48-year-old woman who reported no medical conditions (Fig 4). An implant was placed at the maxillary left first premolar site (implant 5) in 2013. Twelve months later, the implant had an average PD of 4.2 mm and

exhibited erythema, bleeding, and radiographic evidence of bone loss. At the 6-month follow-up, the clinical signs had completely resolved, and the average PD was 3.2 mm. At 18 months posttreatment, radiography indicated complete fill of the defect.

Seven implants (3%) in 7 patients failed following the first treatment. The remaining 41 implants (18%) in 21 patients had incomplete resolution of clinical signs and were scheduled for a second treatment.

### Two treatments

After the second treatment, an additional 24 implant sites (11%) in 15 patients were improved. This group had a baseline mean PD of 5.5 mm, which was reduced by 1.3 mm after the second treatment.

Case 4 is representative of the sample that required 2 treatments before resolution of PD and clinical signs. The patient was a 69-year-old man in good health. In 2004, he underwent a whole-mouth restoration with 10 implants supporting a maxillary prosthesis and 6 implants supporting a mandibular prosthesis. A subsequent change in occlusion resulted in discomfort, erythema, and bleeding on probing at all implants. Pretreatment, the maxillary left central incisor site (implant 9) demonstrated significant periapical involvement (Fig 5). Two treatments, 14 months apart, were needed to control the bleeding. A radiograph obtained 20 months following the first treatment revealed significant improvement in the periapical lesion. At baseline, all 16 implants demonstrated erythema, spontaneous bleeding, and exudate (Fig 6). At 20 months following the first treatment, all clinical signs were absent, and only 3 of 84 pockets probed 5.0 mm.

One implant failed after the second treatment, and 16 implants (7%) in 5 patients were scheduled for a third treatment.

### Three treatments

The 16 implants (7%) that were treated for a third time still exhibited bleeding, erythema, and/or suppuration posttreatment. The mean PDs for the group were reduced by only 0.5 mm from baseline to the third treatment follow-up. These patients had intact implants and were being monitored at the close of the study.

Case 5 is representative of the sample receiving 3 treatments. The patient was an 81-year-old man with multiple medical conditions, including a drug-resistant systemic bacterial infection and cardiovascular disease, and he was immunocompromised. An implant placed at the mandibular right first molar site (implant 30) in August 2013 presented in January 2015 with a mean PD of 6.8 mm, bleeding on probing, severe erythema, and radiographic evidence of bone loss (Fig 7). At the 6-month follow-up visit (June 2015), the erythema had resolved and the mean PD was reduced to 5.5 mm, but there was still bleeding. At that time, the patient received a second LAPIP treatment. At the July 2016 visit, the condition of the site had continued to deteriorate. At that time, the PDs were 12.0 mm at 5 sites and 11.0 mm at the sixth site, and the size of the defect had increased. For the third treatment, the light dose was increased to 305 J at pass 1 and 180 J at pass 2. At the follow-up in November 2016, the implant was still intact and the bleeding had resolved.

### Failed implants

Fifteen implants in 14 patients were recorded as failed during the study period. Patients who had failed implants tended to be older than those who did not, and, in this small sample, women outnumbered men 4:3. Although the baseline PD did not seem to predict implant loss, the occurrence of both bleeding and suppuration at baseline did seem to be a risk factor. Failed implants were more commonly found in patients with multiple medical conditions. It is possible that patients with diabetes mellitus, immunocompromised patients, those taking anticoagulants, and patients with multiple medical conditions are more likely to lose implants.

The changes in clinical signs and PD at first follow-up were compared to the population demographics and medical history to determine any relationship between health factors and outcome. Most sample sizes were too small for valid statistical comparisons, and no obvious relationships among conditions indicated differences in response to therapy within the sample of rescued implants.

### Discussion

This study attempted to present an unbiased and transparent retrospective look at the baseline characteristics and clinical outcomes of a complete cohort of 222 patients treated with the LAPIP protocol within the 3 years from October 2013 to September 2016. The records for this cohort were sometimes incomplete, which is common when retrospective data are studied. This issue can present a challenge when different samples and sample sizes within the cohort are described; however, a sufficient total population with representative dataset was available for a valid statistical analysis of the response to treatment. The baseline data for the subset used for analysis indicated that this sample was representative of the entire cohort. It can be

stated with confidence that the PD reductions and resolution of clinical signs following treatment recorded in the patient records were statistically significant ( $P < 0.001$ ). A survival rate of 94% was recorded at a median (longest follow-up) of 13.1 months for 264 implants.

There appear to be effective minimally invasive treatments for peri-implant mucositis.<sup>1,13,35</sup> The present study examined the treatment of the more advanced peri-implantitis. All of the implants treated with the LAPIP protocol in this study had clinical and radiographic signs to indicate a diagnosis of peri-implantitis. As such, LAPIP treatment results of a 94% survival rate and 90% success rate are best compared to the more invasive regenerative surgeries. The indications for the use of LAPIP treatment at the private practice that was the source of study data are the presence of (1) at least 1 of 6 sites with a PD  $\geq 4$  mm with bleeding and/or a PD of  $\geq 5$  mm with or without clinical signs of infection and (2) radiographic evidence of bone loss (although lingual and buccal defects are not always visible in radiographs). Success for an individual implant is defined as a PD  $\leq 4$  mm and substantial improvement in clinical signs.

Lagervall & Jansson published a similar retrospective analysis of 382 implants with peri-implantitis in 150 patients with a 26-month follow-up.<sup>36</sup> The clinic performed a variety of protocols. Periodontal flap surgery with osteoplasty represented 47% of the cases, and regenerative surgery with bone substitute materials constituted 20% of the cases. The mean success rate at the patient level was 69%. Other examples include Charalampakis et al, who reported a 45% success rate after either nonsurgical therapy or surgical treatment with or without antibiotics, and Serino & Turri, who reported a success rate of 58% after either nonsurgical therapy or surgical treatment with or without antibiotics.<sup>37,38</sup> Aghazadeh et al reported on 71 implants with peri-implantitis in 45 patients; the sites were treated with open flap surgery augmented with autologous or bovine-derived bone grafts and collagen membranes.<sup>39</sup> Success was defined as a PD  $\leq 5$  mm, no more than 1 site with bleeding, and no suppuration. Success rates at 12 months were 13.9% for autologous and 38.5% for bovine-derived bone grafts. The de Waal group tested 2 different treatment protocols—resective surgery with (chlorhexidine plus cetylpyridinium chloride) or without (placebo) decontamination. They reported a 49% success rate in both groups at the 12-month follow-up.<sup>40</sup>

Literature reviews show that many regenerative studies claim PD reductions and some resolution of clinical signs, but none of these studies report survival or success rates above 70%.<sup>2-6</sup> Although certain protocols have shown promising results, no one approach has been demonstrated to be consistently effective. Many of these techniques are still in the research phase and not readily available to the private practitioner. The LAPIP protocol is different because of its current availability and the fact that it is a minimally invasive procedure compared to conventional open flap surgery.

Most types of dental lasers have been validated for their ability to destroy pathogens on implant surfaces and other surfaces that are directly exposed to the laser beam.<sup>21-23</sup> In some resective protocols, decontamination of the implant surface has been attempted using either an Er:YAG (2940 nm) or a CO<sub>2</sub> (10,600 nm) dental laser. Renvert et al, using an Er:YAG laser protocol,

reported that clinical indices decreased by 44% and PD was reduced by 0.8 mm for 55 implants in 21 patients.<sup>25</sup> These results indicate that none of their cases achieved the level of treatment outcomes observed in the present study. Schwarz et al used a different Er:YAG protocol on 38 implants in 32 patients.<sup>41</sup> After treatment, the bleeding scores and clinical attachment levels were not significantly different from the baseline data.

Studies on antimicrobial photodynamic therapy report some positive results with diode laser activation of a topically applied photosensitizer, but success rates are low.<sup>8,42,43</sup> In addition, antimicrobial photodynamic therapy is still experimental.

The primary treatment objective of peri-implantitis therapy is to eliminate the inflammation that is contributing to tissue damage and progressive bone loss. In the present study, post-operative elimination of signs of inflammation and reduction in PDs were considered to represent initial success. Continued hygiene visits, vigilance, and the possibility of additional treatments are essential to maintaining success. Hence, the 94% survival rate is an incomplete description of the response to therapy. In reality, patients demonstrated a continuum of responses. A majority of implants (79%) responded successfully to a single treatment with complete resolution of clinical signs and a PD  $\leq$  4 mm. Some implants treated twice (11%) also responded successfully, representing an initial success rate of 90%. Successfully treated patients entered a program of continued 6-month hygiene visits, an essential part of the LAPIP protocol. Referred patients were counseled on postoperative care and returned to their primary dentist with detailed instructions.

A group of implants representing about 5% of the sample received multiple treatments and continued to have persistent bleeding and PDs  $>$  4 mm. The treatment was successful in maintaining these implants up to a median of 13.1 months, but their long-term results are uncertain.

The group of failed implants, representing 6% of all implants treated, tended to be in older women with multiple medical conditions. No strong trends were observed in this small sample in relation to specific clinical outcomes that could be expected for medical conditions such as smoking and diabetes mellitus.<sup>1,6,44</sup> These implants initially presented with both bleeding and suppuration and had a mean PD of 6.1 mm, indicating a more severe initial disease involvement.

Patients with a history of peri-implantitis are considered to be at risk for recurrence.<sup>45</sup> In the present cohort, about 2 years after treatment, some patients who met the success criteria are presenting with signs of inflammation at hygiene visits and may require additional treatment.

## Conclusion

This documentation of the clinical outcomes from an active private practice provides insights into the efficacy of LAPIP treatment for peri-implantitis. In the recorded cases, the minimally invasive LAPIP approach provided effective and predictable clinical outcomes. The primary outcome variable, reduction in PD, was statistically significant ( $P < 0.001$ ). Efficacy, defined as implants exhibiting improvement in PD at the first follow-up in those implants with complete PD data, was 103 of 116 implants (89%). At the first follow-up (median 7.6 months), bleeding was reduced by 78%. Suppuration was reduced by 83% and erythema

by 85%. All decreases in secondary outcome measures were statistically significant ( $P < 0.001$ ).

Most implants (90%) had a PD  $\leq$  4 mm and elimination of clinical signs after the first or second treatment. About 5% of implants received multiple treatments but continued to demonstrate clinical signs of peri-implantitis and PD  $\geq$  4.

Medical conditions, the severity of initial clinical signs, age, and female sex were all probable risk factors for treatment failure. Fifteen (6%) of 264 implants failed, while 249 were intact at 13.1 months (median longest follow-up time), for a survival rate of 94%.

Despite these successes, the patient population, the implants, and the measurement techniques are not standardized in a retrospective review. Therefore, while promising, these preliminary results must be considered specific to this practice. Future randomized controlled trials are indicated.

## Author information

Dr Schwarz is in private practice, McAllen, Texas. Dr Harris is volunteer faculty, Department of Biological Sciences, California State University Chico, and an instructor, Department of Periodontics, Rutgers School of Dental Medicine, Newark, New Jersey.

## Disclosure

Dr Harris is chief science advisor for Millennium Dental Technologies, Cerritos, California, and director of Bio-Medical Consultants & Associates, Paradise, California.

## References

- Lindhe J, Meyle J; Group D of European Workshop on Periodontology. Peri-implant diseases: consensus report of the sixth European workshop on periodontology. *J Clin Periodontol*. 2008;35(8 Suppl):282-285.
- Esposito M, Grusovin MG, Worthington HV. Treatment of peri-implantitis: what interventions are effective? A Cochrane systematic review. *Eur J Oral Implantol*. 2012;(5 Suppl):S21-S41.
- Alani A, Bishop K. Peri-implantitis, part 3: current modes of management. *Br Dent J*. 2014;217(7):345-349.
- Elemek E, Almas K. Peri-implantitis: etiology, diagnosis and treatment: an update. *N Y State Dent J*. 2014;80(1):26-32.
- Heitz-Mayfield LJ, Mombelli A. The therapy of peri-implantitis: a systematic review. *Int J Oral Maxillofac Implants*. 2014;(29 Suppl):325-345.
- Robertson K, Shahbazian T, MacLeod S. Treatment of peri-implantitis and the failing implant. *Dent Clin North Am*. 2015;59(2):329-343.
- Froum SJ, Dagba AS, Shi Y, Perez-Asenjo A, Rosen PS, Wang WCW. Successful surgical protocols in the treatment of peri-implantitis: a narrative review of the literature. *Implant Dent*. 2016;25(3):416-426.
- Romeo U, Nardi GM, Libotte F, Sabatini S, Palaia G, Grassi FR. The antimicrobial photodynamic therapy in the treatment of peri-implantitis. *Int J Dent*. 2016;2016:7692387.
- Karring ES, Stavropoulos A, Ellegaard B, Karring T. Treatment of peri-implantitis by the Vector system. *Clin Oral Implants Res*. 2005;16(3):288-293.
- Persson GR, Samuelsson E, Lindahl C, Renvert S. Mechanical non-surgical treatment of peri-implantitis: a single-blinded randomized longitudinal clinical study. II. Microbiological results. *J Clin Periodontol*. 2010;37(6):563-573.
- Renvert S, Lessem J, Dahlén G, Renvert H, Lindahl C. Mechanical and repeated antimicrobial therapy using a local drug delivery system in the treatment of peri-implantitis: a randomized clinical trial. *J Periodontol*. 2008;79(5):836-844.
- Sahm N, Becker J, Santel T, Schwarz F. Non-surgical treatment of peri-implantitis using an air-abrasive device or mechanical debridement and local application of chlorhexidine: a prospective, randomized, controlled clinical study. *J Clin Periodontol*. 2011;38(9):872-878.
- Machtei EE. Treatment alternatives to negotiate peri-implantitis. *Adv Med*. 2014;2014:487903.
- Romanos GE, Nentwig GH. Regenerative therapy of deep peri-implant infrabony defects after CO<sub>2</sub> laser implant surface decontamination. *Int J Periodontics Restorative Dent*. 2008;28(3):245-255.

15. Persson GR, Roos-Jansåker AM, Lindahl C, Renvert S. Microbiologic results after non-surgical erbium-doped:yttrium, aluminum, and garnet laser or air-abrasive treatment of peri-implantitis: a randomized clinical trial. *J Periodontol*. 2011;82(9):1267-1278.
16. Schwarz F, John G, Mainusch S, Sahn N, Becker J. Combined surgical therapy of peri-implantitis evaluating two methods of surface debridement and decontamination. A two-year clinical follow up report. *J Clin Periodontol*. 2012;39(8):789-797.
17. Kim DM, Nevins M, Camelo M, et al. The feasibility of demineralized bone matrix and cancellous bone chips in conjunction with an extracellular matrix membrane for alveolar ridge preservation: a case series. *Int J Periodontics Restorative Dent*. 2011;31(1):39-47.
18. Nevins ML, Carmelo M, Schupbach P, Kim SW, Kim DM, Nevins M. Human clinical and histologic evaluation of laser-assisted new attachment procedure. *Int J Periodontics Restorative Dent*. 2012;32(5):497-507.
19. Schwarz F, Sculean A, Bieling K, Ferrari D, Rothamel D, Becker J. Two-year clinical results following treatment of peri-implantitis lesions using a nanocrystalline hydroxyapatite or a natural bone mineral in combination with a collagen membrane. *J Clin Periodontol*. 2008;35(1):80-87.
20. Schwarz F, Sahn N, Bieling K, Becker J. Surgical regenerative treatment of peri-implantitis lesions using a nanocrystalline hydroxyapatite or a natural bone mineral in combination with a collagen membrane: a four-year clinical follow-up report. *J Clin Periodontol*. 2009;36(9):807-814.
21. Giannelli M, Bani D, Tani A, et al. In vitro evaluation of the effects of low-intensity Nd:YAG laser irradiation on the inflammatory reaction elicited by bacterial lipopolysaccharide adherent to titanium dental implants. *J Periodontol*. 2009;80(6):977-984.
22. Gonçalves F, Zanetti AL, Zanetti RV, et al. Effectiveness of 980-nm diode and 1064-nm extra-long-pulse neodymium-doped yttrium aluminum garnet lasers in implant disinfection. *Photomed Laser Surg*. 2010;28(2):273-280.
23. Kamel MS, Khosa A, Tawse-Smith A, Leichter J. The use of laser therapy for dental implant surface decontamination: a narrative review of in vitro studies. *Lasers Med Sci*. 2014;29(6):1977-1985.
24. Azzeh MM. Er,Cr:YSGG laser-assisted surgical treatment of peri-implantitis with 1-year reentry and 18-month follow-up. *J Periodontol*. 2008;79(10):2000-2005.
25. Renvert S, Lindahl C, Roos Jansåker AM, Persson GR. Treatment of peri-implantitis using an Er:YAG laser or an air-abrasive device: a randomized clinical trial. *J Clin Periodontol*. 2011;38(1):65-73.
26. Deppe H, Horch HH, Neff A. Conventional versus CO2 laser-assisted treatment of peri-implant defects with the concomitant use of pure-phase  $\beta$ -tricalcium phosphate: a 5-year clinical report. *Int J Oral Maxillofac Implants*. 2007;22(1):79-86.
27. Mailloa J, Lin GH, Chan HL, MacEachern M, Wang HL. Clinical outcomes of using lasers for peri-implantitis surface detoxification: a systematic review and meta-analysis. *J Periodontol*. 2014;85(9):1194-1202.
28. Honigman AS. Laser-assisted peri-implantitis procedure: redefining the treatment of peri-implantitis. *Dentaltown*. 2013;14(9):82-84,86.
29. Suzuki JB. Salvaging implants with an Nd:YAG laser: a novel approach to a growing problem. *Compend Contin Educ Dent*. 2015;36(10):756-761.
30. Nicholson D, Blodgett K, Braga C, et al. Pulsed Nd:YAG laser treatment for failing dental implants due to peri-implantitis. In: Rechman P, Fried D, eds. *Lasers in Dentistry XX*. Proceedings vol 8929. Bellingham, WA: Society of Photo-Optical Instrumentation Engineers; 2014:89290H-1-89290H-14. <https://www.spiedigitallibrary.org/conference-proceedings-of-spie/8929/1/Pulsed-Nd-YAG-laser-treatment-for-failing-dental-implants-due/10.1117/12.2041037.short>.
31. Harris DM. Dosimetry for laser sulcular debridement. *Lasers Surg Med*. 2003;33(4):217-218.
32. Yukna RA, Carr RL, Evans GH. Histologic evaluation of an Nd:YAG laser-assisted new attachment procedure in humans. *Int J Periodontics Restorative Dent*. 2007;27(6):577-587.
33. Sanz M, Chapple IL; Working Group 4 of the VIII European Workshop on Periodontology. Clinical research on peri-implant diseases: consensus report of Working Group 4. *J Clin Periodontol*. 2012;39(Suppl 12):202-206.
34. American Academy of Periodontology. *Glossary of Periodontal Terms*. <https://members.perio.org/libraries/glossary?ssopc=1>. Accessed March 5, 2020.
35. Mahato N, Wu X, Wang L. Management of peri-implantitis: a systematic review, 2010-2015. *Springerplus*. 2016;5:105.
36. Lagerwall M, Jansson LE. Treatment outcome in patients with peri-implantitis in a periodontal clinic: a retrospective study. *J Periodontol*. 2013;84(10):1365-1373.
37. Charalampakis G, Rabe P, Leonhardt A, Dahlén G. A follow-up study of peri-implantitis cases after treatment. *J Clin Periodontol*. 2011;38(9):864-871.
38. Serino G, Turri A. Outcome of surgical treatment of peri-implantitis: results from a 2-year prospective clinical study in humans. *Clin Oral Implants Res*. 2011;22(11):1214-1220.
39. Aghazadeh A, Rutger Persson G, Renvert S. A single-centre randomized controlled clinical trial on the adjunct treatment of intra-bony defects with autogenous bone or a xenograft: results after 12 months. *J Clin Periodontol*. 2012;39(7):666-673.
40. de Waal YCM, Raghoobar GM, Huddleston Slater JJ, Meijer HJ, Winkel EG, van Winkelhoff AJ. Implant decontamination during surgical peri-implantitis treatment: a randomized, double-blind, placebo-controlled trial. *J Clin Periodontol*. 2013;40(2):186-195.
41. Schwarz F, Sahn N, Iglhaut G, Becker J. Impact of the method of surface debridement and decontamination on the clinical outcome following combined surgical therapy of peri-implantitis: a randomized controlled clinical study. *J Clin Periodontol*. 2011;38(3):276-284.
42. Schär D, Ramseier CA, Eick S, Arweiler NB, Sculean A, Salvi GE. Anti-infective therapy of peri-implantitis with adjunctive local drug delivery or photodynamic therapy: six-month outcomes of a prospective randomized clinical trial. *Clin Oral Implants Res*. 2013;24(1):104-110.
43. Bassetti M, Schär D, Wicki B, et al. Anti-infective therapy of peri-implantitis with adjunctive local drug delivery or photodynamic therapy: 12-month outcomes of a randomized controlled clinical trial. *Clin Oral Implants Res*. 2014;25(3):279-287.
44. Heitz-Mayfield LJ, Huynh-Ba G. History of treated periodontitis and smoking as risks for implant therapy. *Int J Oral Maxillofac Implants*. 2009;24(Suppl):39-68.
45. Krebs M, Kesar N, Begić A, von Krockow N, Nentwig GH, Weigl P. Incidence and prevalence of peri-implantitis and peri-implant mucositis 17 to 23 (18.9) years postimplant placement. *Clin Implant Dent Relat Res*. 2019;21(6):1116-1123.